

# 257 Incidental Appendectomies During Total Laparoscopic Hysterectomy

Katherine A. O'Hanlan, MD, Deidre T. Fisher, MD, Michael S. O'Holleran, MD

## ABSTRACT

**Objective:** This retrospective observational report analyzes the demographics, blood loss, length of surgical duration, number of days in the hospital, and complications for 821 consecutive patients undergoing total laparoscopic hysterectomy over a 11-year period stratified by incidental appendectomy.

**Methods:** A retrospective chart abstraction was performed. ANOVA and chi-square tests were performed with significance preset at  $P < 0.05$ .

**Results:** Of 821 consecutive patients undergoing total laparoscopic hysterectomy, 257 underwent elective appendectomy with the ultrasonic scalpel, either as part of their staging, treatment for pelvic pain, or prophylaxis against appendicitis. Comparing the 2 groups, no difference existed in mean age of  $50 \pm 10$  years or mean BMI of  $27.6 \pm 6.7$ . Both groups had a similar mean blood loss of 130 mL. Surgery took less time (137 vs 118 minutes,  $P < 0.0012$ ) and the hospital stay was shorter in the appendectomy group (1.5 vs 1.2,  $P < 0.0001$ ) possibly because it was performed incidentally in most cases. No complications were attributable to the appendectomy, and complication types and rates in both groups were similar. Though all appendices appeared normal, pathology was documented in 9%, including 3 carcinoid tumors.

**Conclusions:** Incidental appendectomy during total laparoscopic hysterectomy is not associated with significant risk and can be routinely offered to patients planning elective gynecologic laparoscopic procedures, as is standard for open procedures.

**Key Words:** Incidental appendectomy, Laparoscopy, Total laparoscopic hysterectomy.

## INTRODUCTION

Incidental appendectomy during gynecological procedures has been reviewed in the literature since 1967 and is considered safe and reasonable during both abdominal and vaginal surgeries.<sup>1-8</sup> Nezhat and Nezhat<sup>9</sup> reported on therapeutic laparoscopic appendectomy for the treatment of pelvic pain and concluded the benefits outweigh the minimal risks. It is not known whether incidental laparoscopic appendectomy can be done safely and routinely in gynecologic surgery. We reviewed our database of 821 cases of total laparoscopic hysterectomy (TLH) in which 257 patients had elective appendectomy and report on the safety of this procedure.

## METHODS

We have maintained an anonymous database of TLH cases performed on consecutive patients in each of the following diagnostic categories: benign gynecologic indications and early malignancies limited to Stage IA2 or less cervical cancer, occult ovarian cancer, and clinical Stage IIIA or less endometrial cancer. Investigational Review Board approval is maintained at Sequoia Hospital in Redwood City, CA, USA. In all of these patients, a simple hysterectomy was performed alone or with other procedures as indicated by the patient's history, physical examination, and radiological examinations. Every surgery was performed by the author (KAO'H) from September 5, 1996 to April 4, 2007, at 4 California hospitals. A categorical obstetrics and gynecology resident, a gynecologist, or a general surgeon assisted all surgeries.

The technique used for TLH is described elsewhere in the gynecologic literature.<sup>10</sup> After the hysterectomy, an appendectomy was performed in 257 patients, incising the mesoappendix with a 5-mm Harmonic scalpel or LigaSure (Covidian, Boulder, CO, USA) (Ethicon Endo-Surgery, Cincinnati, OH, USA), to the base at the cecum, then ligating the base with a 0-Vicryl EndoLoop (Ethicon Sutures, Piscataway, NJ, USA). The appendix was then incised across the base with the Harmonic scalpel or LigaSure (**Figure 1**). A ring forceps was passed through the vagina to grasp the appendix at the open base and remove it from the abdominal cavity.

Gynecologic Oncology Associates, Palo Alto, California, USA (Dr. O'Hanlan).

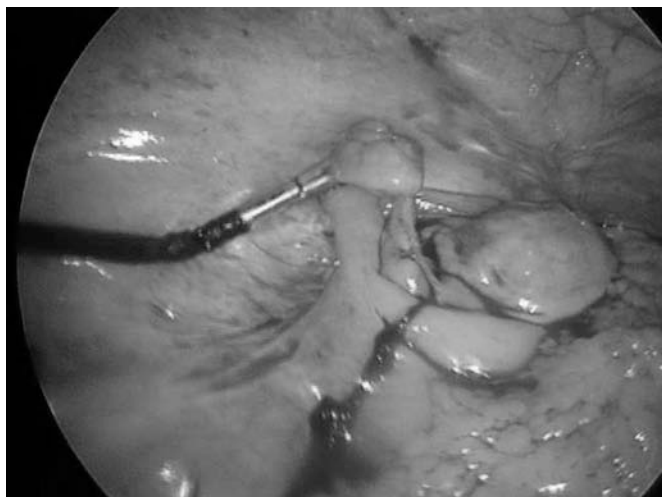
Atlanta Center for Special Pelvic Surgery, Atlanta, Georgia, USA (Dr. Fisher).

General Surgery Associates, San Carlos, California, USA (Dr. O'Holleran).

Drs O'Holleran and Fisher have no conflict of interest. Dr. O'Hanlan is a consultant for Novare Surgical Systems and is a speaker for Ethicon EndoSurgery. No financial support was received for this article. No off-label use of any product is discussed or described.

Address reprint requests to: Kate O'Hanlan, MD, Gynecologic Oncology Associates, 4370 Alpine Road, Suite 104, Portola Valley, CA 94028, USA. Telephone: 650 851 6669, Fax: 650 851 9747, E-mail: ohanlan@AOL.com

© 2007 by JSLs, *Journal of the Society of Laparoendoscopic Surgeons*. Published by the Society of Laparoendoscopic Surgeons, Inc.



**Figure 1.** The appendix is held with the Realhand (Novare Surgical Systems, Cupertino, CA, USA) in preparation for incision of the mesentery.

By using JMP statistical software (SAS, Cary, NC, USA), continuous data were analyzed by ANOVA, and categorical data were analyzed by chi-square and Fisher's exact test, with significance set at  $P < 0.05$ .

## RESULTS

Of 821 women undergoing TLH, 257 underwent concomitant appendectomy and 564 did not. The mean age of 50 ( $P = 0.1404$ ) and mean body mass index (BMI) of 27 ( $P = 1823$ ) were similar in both groups.

Surgical blood loss was similar in both groups, 130 mL ( $P = 0.0678$ ). The mean duration of surgery was 19 minutes shorter in the appendectomy group, (137 vs 122 minutes,  $P < 0.0012$ ). Patients in the appendectomy group spent fewer days in the hospital (1.5 vs 1.2,  $P < 0.0001$ ). If patients with long additional procedures performed, such as node dissection, omentectomy, Burch colposuspension, uterosacral ligament plication, cholecystectomy, herniorrhaphy, or posterior vaginal repair, were eliminated from the analysis, leaving only 482 patients undergoing only hysterectomy/BSO, appendectomy, lysis of adhesions, and fulguration (not resection) of endometriosis, the appendectomy cases still were of shorter duration (133 vs 104 minutes,  $P < 0.0001$ ), and the duration of stay was still shorter in the appendectomy group (1.5 vs 1.1,  $P < 0.0001$ ).

Clinically, all 257 appendices appeared normal. Pathologic examination of the appendices revealed normal anatomy in 135 (52%); fibrous obliteration in 98 (38%);

endometriosis in 8 (4%); 3 cases each of carcinoid tumor (1.1%) and chronic appendicitis (1.1%); 2 cases each of serositis fatty metaplasia and mucinous cystadenoma (1.1%); and one case each of mucosal melanosis, neurophilia, adhesions, and metastatic papillary ovarian carcinoma (1.5%). Two of the three cases of carcinoid demonstrated invasion to the serosal surface and required subsequent staging ileoascending colectomy as treatment.

No complications were attributed to the appendectomy procedure. Additionally, there was no difference in overall (11.3 vs 7.4%,  $P = 0.0813$ ), or reoperative complications (5.6 vs 2.7%,  $P = 0.0654$ ) in either group.

## DISCUSSION

In patients 40 years and older, appendicitis occurs with a frequency of about 30/100,000,<sup>11</sup> about the same as the incidence of ovarian cancer in that age group.<sup>12</sup> After age 60, patients who develop appendicitis have a significantly increased risk of perforation and postoperative complications.<sup>13</sup> This is because the diagnosis of appendicitis in senior women is often difficult, making immediate open surgical exploration appropriate in this population.<sup>14</sup> In 1981, Tranmer et al<sup>6</sup> reviewed 100 cases of appendicitis among women over age 40 and found a 30% perforation rate and a 31% risk of incisional abscess. Furthermore, among these women, 13% had undergone previous elective hysterectomy or cholecystectomy, leading them to conclude that some of these cases may have been prevented by incidental appendectomy.

The earliest reports of incidental appendectomy in gynecologic surgery were during Cesarean deliveries in 1959,<sup>15</sup> for management of ectopic pregnancy in 1962,<sup>16</sup> vaginal hysterectomy in 1966,<sup>8</sup> with abdominal hysterectomy in 1967,<sup>17</sup> and during postpartum sterilizations in 1973.<sup>18</sup> The routine performance of incidental appendectomy during laparotomy for ovarian cancer staging had become standard by 1968 because 25% of normal-appearing appendices contained metastatic deposits.<sup>6</sup> In 1981, Tranmer et al<sup>6</sup> reviewed 200 cases of incidental appendectomy during laparotomy for hysterectomy or cholecystectomy, noting no complications, concluding that incidental appendectomy was indeed routinely indicated with laparotomy. Waters et al<sup>19</sup> concurred that incidental appendectomy "should be performed with abdominal and pelvic surgery whenever the opportunity is presented." In a review of 5,369 incidental appendectomies, 8% of specimens demonstrated acute appendicitis, 65% showed evidence of chronic appendicitis with obliteration of the lumen, and

0.6% contained carcinoid tumors, mucocèles, or endometriosis.<sup>20</sup> These data are reconfirmed by our findings.

Incidental appendectomy has been recommended for routine use with all abdominal hysterectomies by Salom et al,<sup>1</sup> who also observed no additional complications and confirmed a 31% rate of appendiceal pathology.<sup>2</sup> By 1988, routine incidental appendectomy during laparotomy was accepted as safe and protective,<sup>4,20</sup> with some hospital programs enforcing a policy of routine incidental appendectomy during all open gynecologic surgery.<sup>21</sup> They reported 97% compliance with the policy with no increase in complication rates attributed to the appendectomy.<sup>21</sup>

Initially, in the late 1970s, laparoscopy for appendicitis was used solely to confirm the diagnosis and to facilitate the planned laparotomy for appendectomy.<sup>22–24</sup> After the 1987 separate reports of laparoscopic therapeutic appendectomies by Gangal and Gangal<sup>25</sup> and Schrieber,<sup>26</sup> the laparoscopic approach for therapeutic appendectomy became standard.<sup>27</sup>

A laparoscopic approach for incidental appendectomy in elective gynecologic surgery was first reported in 1982 by Semm<sup>28</sup> and then in a 1990 series of 388 gynecologic procedures by Gotz et al,<sup>29</sup> and in a 1991 series of 100 procedures by Nezhat and Nezhat,<sup>9</sup> with no complications attributable to the procedure. In 1996, Pelosi and Pelosi<sup>30</sup> performed 12 vaginal incidental appendectomies during laparoscopic-assisted vaginal hysterectomies and found that an additional 12 minutes was needed for the procedure. Incidental laparoscopic appendectomy is specifically recommended in cases of right pelvic pain because 22 of 53 patients had appendiceal inflammation, even though removal did not relieve the pain in all patients.<sup>31</sup> Many patients having laparoscopic surgery for endometriosis have been found to have endometriosis on the appendix.<sup>32</sup> Neither fertility concerns<sup>33,34</sup> nor pregnancy<sup>35</sup> are contraindications for incidental or indicated appendectomy in young women.<sup>33,34</sup> Today, laparoscopic therapeutic appendectomy is part of the gynecologic surgical standard for treatment of pelvic pain and endometriosis,<sup>36,37</sup> and staging of ovarian and tubal carcinoma.<sup>38</sup>

In this series of total laparoscopic hysterectomy patients with many diverse gynecological indications, no detriment was observed that was attributable to the appendectomy. The longer surgical duration and postoperative hospital stay in the group not having appendectomy are likely due to the fact that appendectomy was variably offered and variably performed. This is a significant weakness in this report, but it reflects the reality of surgical practice standards. Although appendectomy was recommended to

every patient under age 40, we did not document the rate of acceptance or refusal. Additionally, we did not uniformly offer or document the response for appendectomy to every patient over age 40. Early in the series, appendectomy was rarely offered to patients over age 40. When a case seemed overly long or difficult, the appendectomy was sometimes abandoned. These data, however, are still useful in confirming that laparoscopic incidental appendectomy is low risk when the appendix is accessible and when the prior portions of the case have gone well.

## CONCLUSION

This series of 199 cases is the largest series of laparoscopic incidental appendectomies in gynecology and confirms an equal and low complication rate whether appendectomy was performed or not. These data concur with the literature findings of safety from routine incidental appendectomy during open or laparoscopic approaches. Gynecologists should consider offering prophylactic appendectomy to their patients when open or laparoscopic procedures are planned.

## References:

1. Salom EM, Schey D, Penalver M, et al. The safety of incidental appendectomy at the time of abdominal hysterectomy. *Am J Obstet Gynecol.* 189:1563–1567, 2003; discussion 1567–1568.
2. Snyder TE, Selanders JR. Incidental appendectomy—yes or no? A retrospective case study and review of the literature. *Infect Dis Obstet Gynecol.* 1998;6:30–37.
3. Kovac SR, Cruikshank SH. Incidental appendectomy during vaginal hysterectomy. *Int J Gynaecol Obstet.* 1993;43:62–63.
4. Voitek AJ, Lowry JB. Is incidental appendectomy a safe practice? *Can J Surg.* 1988;31:448–451.
5. Shao JY. [Analysis of 527 cases with incidental appendectomy in gynecologic operation]. *Zhonghua Fu Chan Ke Za Zhi.* 1987;22(3):141–143, 189.
6. Tranmer BI, Graham AM, Sterns EE. Incidental appendectomy?—Yes. *Can J Surg.* 1981;24(2):191–192.
7. Lausten GS, Nielsen GV, Kisku RL. [Incidental appendectomy in abdominal hysterectomy]. *Ugeskr Laeger.* 1981;143(18):1154–1156.
8. McGowan L. Incidental appendectomy during vaginal surgery. *Am J Obstet Gynecol.* 1966;95(4):588.
9. Nezhat C, Nezhat F. Incidental appendectomy during video-laseroscopy [see comments]. *Am J Obstet Gynecol.* 1991;165(3):559–564.
10. O'Hanlan KA, Huang GS, Garnier AC, et al. Total laparo-

- scopic hysterectomy versus total abdominal hysterectomy: cohort review of patients with uterine neoplasia. *JLS*. 2005;9(3):277–286.
11. Andersson R, Hugander A, Thulin A, Nystrom PO, Olaison G. Indications for operation in suspected appendicitis and incidence of perforation. *BMJ*. 1994;308(6921):107–110.
  12. Quirk JT, Natarajan N. Ovarian cancer incidence in the United States, 1992–1999. *Gynecol Oncol*. 2005;97(2):519–523.
  13. Andersson A, Bergdahl L. Acute appendicitis in patients over sixty. *Am Surg*. 1978;44(7):445–447.
  14. Lunca S, Bouras G, Romedea NS. Acute appendicitis in the elderly patient: diagnostic problems, prognostic factors and outcomes. *Rom J Gastroenterol*. 2004;13(4):299–303.
  15. Davis ME. Gynecologic operations at cesarean section. *Clin Obstet Gynecol*. 1959;2:1095–1106.
  16. Atherton HE, Lado M. Auxiliary surgery with operation for ectopic pregnancy. *Memphis Mid South Med J*. 1962;37:143–145.
  17. Loeffler F, Stearn R. Abdominal hysterectomy with appendectomy. *Acta Obstet Gynecol Scand*. 1967;46(3):435–443.
  18. Wilson EA, Dilts PV, Jr., Simpson TJ. Appendectomy incidental to postpartum sterilization procedures. *Am J Obstet Gynecol*. 1973;116(1):76–81.
  19. Waters EG. Elective appendectomy with abdominal and pelvic surgery. *Obstet Gynecol*. 1977;50(5):511–517.
  20. Krone HA, Sperke E. Preventive appendectomy in gynecologic surgery. Report of 1,718 cases [in German]. *Geburtshilfe Frauenheilkd*. 1989;49(12):1035–1038.
  21. Westermann C, Mann WJ, Chumas J, Rochelson B, Stone ML. Routine appendectomy in extensive gynecologic operations. *Surg Gynecol Obstet*. 1986;162(4):307–312.
  22. Steptoe P. Research and other horizons in laparoscopy. *J Reprod Med*. 1976;16(4):179–183.
  23. de Kok HJ. A new technique for resecting the non-inflamed not-adhesive appendix through a mini-laparotomy with the aid of the laparoscope. *Arch Chir Neerl*. 1977;29(3):195–198.
  24. Fleming JS. Laparoscopically directed appendectomy. *Aust N Z J Obstet Gynaecol*. 1985;25(3):238–240.
  25. Gangal HT, Gangal MH. Laparoscopic appendectomy. *Endoscopy*. 1987;19(3):127–129.
  26. Schreiber JH. Early experience with laparoscopic appendectomy in women. *Surg Endosc*. 1987;1(4):211–216.
  27. Bresciani C, Perez RO, Habr-Gama A, et al. Laparoscopic versus standard appendectomy outcomes and cost comparisons in the private sector. *J Gastrointest Surg*. 2005;9(8):1174–1181.
  28. Semm K. Advances in pelviscopic surgery. *Prog Clin Biol Res*. 1982;112 Pt B:127–149.
  29. Gotz F, Pier A, Bacher C. Modified laparoscopic appendectomy in surgery. A report on 388 operations. *Surg Endosc*. 1990;4(1):6–9.
  30. Pelosi MA, 3rd, Pelosi MA. Vaginal appendectomy at laparoscopic-assisted vaginal hysterectomy: a surgical option. *J Laparoendosc Surg*. 1996;6(6):399–403.
  31. Popovic D, Kovjanic J, Milostic D, et al. Long-term benefits of laparoscopic appendectomy for chronic abdominal pain in fertile women. *Croat Med J*. 2004;45(2):171–175.
  32. Urbach DR, Reedijk M, Richard CS, Lie KI, Ross TM. Bowel resection for intestinal endometriosis. *Dis Colon Rectum*. 1998;41(9):1158–1164.
  33. Viktrup L, Hee P. Fertility and long-term complications four to nine years after appendectomy during pregnancy. *Acta Obstet Gynecol Scand*. 1998;77(7):746–750.
  34. Andersson R, Lambe M, Bergstrom R. Fertility patterns after appendectomy: historical cohort study. *BMJ*. 1999;318(7189):963–967.
  35. Adam VN, Mrcic V, Smiljanic A, Cala Z. Laparoscopic surgery during pregnancy [in Croatian]. *Lijec Vjesn*. 126(7–8):201–203, 2004.
  36. Nezhat CH, Seidman D, Nezhat F, Nezhat CR. Comparison of laparoscopic appearance of appendix and resulting pathology. *Obstet Gynecol*. 2000;95(4 Suppl 1):S34.
  37. Carter JE. Laparoscopic treatment of chronic pelvic pain in 100 adult women. *J Am Assoc Gynecol Laparosc*. 1995;2(3):255–262.
  38. Querleu D, LeBlanc E. Laparoscopic infrarenal paraaortic lymph node dissection for restaging of carcinoma of the ovary or fallopian tube. *Cancer*. 1994;73(5):1467–1471.